

Pediatric Surgery

el exam kan 2day essay 3ala 3'eer el 3ada 5Q:

complication of varicocele

complication of simple goiter

complication of hernia

diagnostic features of hydrocele

.....strangulated herniaSee more

bl nesba lel clinical:

dr.noor el 5oly (case hernia(

what is different between management of direct and indirect inguinal hernia

what are types of hernioraphy

what is complications of hernia

what is the difference between obstructed and strangulated hernia

what is the difference between strangulated and incarcerated hernia

w 3amatan howa 3ata kol el nas el full mark

dr.saber waheeb (case hernia(

what is your diagnosis?

what is meant by hernia?

what is meant by impulse on cough?

why indirect?

complications of hernia?

w kan fe kaman case undescended testis bs lessa ma3reftesh etsa2al 3aleha eih

de shewayat as2ela MCQ el mafrood en de ele gat fl exams abl keda
incase 3'ayaro ra2yohom fe emte7an el round w bardo yenfa3o f a5er el
sana:

Q. most appropriate age of Rx of congenital inguinal hernia:

- once diagnosed
- on childhood
- at puberty

Q. same question but diff. choices:

- ١-year
- ٢-years
- ٣-years

Q. same question but diff. choices:

- neonate
- infantile
- childhood

(الفكرة اننا دايمة نختار اصغر

age(

Q. herniotomy to adult , which is more important:

- identify vas and vessels
- identify sac
- both of equal importance

Q.herniotomy to child(pediatric) ,which is more important:

-same choices of above Q.

ANS. identify vas and vessels

Q.most common types of repair in Rx. of CONGENITAL inguinal hernia:

-lytle's repair

-shouldice repair

-non of the above

ANS. non of the above as the in CONGENITAL inguinal hernia there is NO repair but just herniotomy

Q. which is more common in congenital hernia:

-direct

-indirect

-both of the above

N.B.fibrous tissue formation is more imp.in hernia surgery(مش الشد)

N.B. Q. مين عدو الجراحة؟

ANS. tension (as it causes disruption of blood vessels)

Q.most advanced Rx. for hernia in adults

ANS. tension free hernioplasty (Lichtenstein)

N.B. herniorraphy = herniotomy + local tissue

N.B. hernioplasty = herniotomy + mesh

Q.Rx of congenital inguinal hernia:

- herniotomy
- herniorraphy
- hernioplasty

ANS. herniotomy

QUESTIONS FOR CLINICAL:

VIP. Q. complications

- types of complications
- how to differentiate between them
- how to treat them

Q.maydle's hernia (hernia in w(

Q.types of hernia where strangulation occurs without obstruction

ANS .

- if not intestine
- if omentum

- if the content is -appendix
- meckel's diverticulum= littre's hernia
- part of circumference = richter's hernia

Q.Rx of retractile testis?

- mostly reassurance

Q cause of retractile testes?

- hyperactive cremasteric reflex

Q which is more important in orchiopexy?

- cord lengthening

Q. most advanced technique for impalpable testes?

- gradual traction

Q most important diagnostic tool for impalpable testes?

- laparoscopy

Q most appropriate age for operation of undescended testes?

- 6-months -1 year

Q, most appropriate age for operation of undescended testes is at 6 months except if?

-associated with hernia

Q most advanced technique for meatoplasty?

-TIP (tubularised incised plate) (transurethral incision of the plate)
(snodgrass technique)

Q most common type of oesophageal atresia?

-oesophageal atresia with fistula between trachea and distal pouch

Q most accurate diagnostic tool for oesophageal atresia with fistula between trachea and distal pouch?

-failure to pass nasogastric tube

Q most common type of congenital diaphragmatic hernia?

-Boerhaave (posterolateral)

Q most common site for aganglionic or Hirschsprung disease is?

-rectosigmoid (75%)

Q most important symptom of Hirschsprung disease?

delayed passage of meconium

Q most advanced technique for Rx of Hirschsprung disease?

- minimally invasive
 - laparoscopy
 - TAPT (transanal pull through)
-)ALL ARE TRUE(

Q most common type of intussusception in pediatric age group?

- 1 -ry intussusception

Q most common site of intussusception in pediatric age

- ileocecal

Q Rx of congenital pyloric stenosis?

ramsted pyloromyotomy

Q most important symptom for congenital pyloric stenosis?

projectile vomiting

Q most important presenting symptom for intussusception?

red current jelly stool

Q most common cause of intestinal obstruction in

- neonates----- atresia
- infant-----1ry intussusception
- adult----- adhesion.....,.....,

our exam.....29 /6 ..kan short essay 5 questions:

- .١ treatment of intestinal obstruction.
- .٢ treatment of pyloric stenosis
- .٣ diagnosis of impalpable testes
- .٤ diagnosis of hirschsprung disease.
- .٥ types of congenital diaphragmatic hernia.

exam (2/8) 14 MCQ (

- ١ most common type of hypospadias >> distal
- ٢ Incidence of hypospadias >> 1:300
- ٣ optimum age for hyposp. surgery >> 6m:2yrs
- ٤ most common type of CDH is due to >> defect in pleuroperit. fold
- ٥ cause of death in neonate e CDH >> pulmonary hypoplasia
- ٦ Hirschsprung (HSD) all true except >> most common in girls
- ٧ Affected seg in HSD shows all except >> Dilated segment
- ٨ Barium enema in HSD all true except >> conclusive in 100 % of cases
- ٩ best Dx for impalpable testes is >> laparoscopy
- ١٠ Dx of congenital pyloric stenosis all except >> bilious vomiting
- ١١ commonest age for intussusception is >> 5:10 mnth
- ١٢ pyloric stenosis all except >> responds to medical Rx

السنة دي GIT امتحان ال

A-5 mcq

B- 5 enumeration

C- صور اوسكي 6

غياب 1.5

ال mcq

Most common hernia --- indirect inguinal hernia

Stone in bile duct --- mirrizi's \$

Portal vein.. Superior mesenteric vein, splenic vien

Gall Bladder palpable in all except cancer head of pancreas مش

hilar فيه ناس كانت بتقول متأكد

Strangulated hernia.. No impulsive on cough

Enumeration

2 causes of hematemesis

Difference between direct and indirect hernia

Treatment of oesophageal varices.. Stepwise بالترتيب يعني

Preoperative preparation in cholecystectomy

2 non mid line ventral hernias

slides

...

Kocher forceps

Crushing intestinal clamp

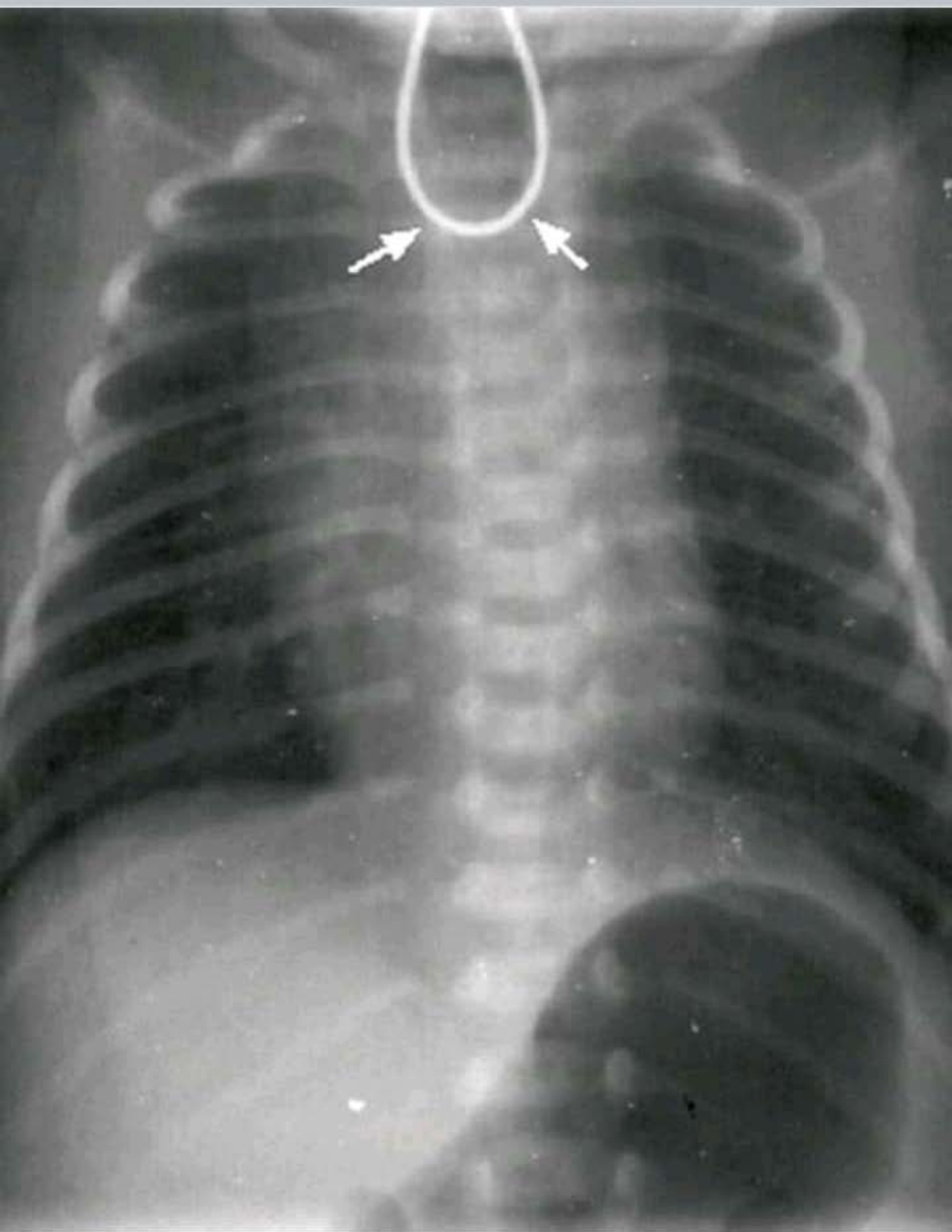
Gallstone forceps

Perforated peptic ulcer,

Xray intestinal obstruction

T tube cholangiography

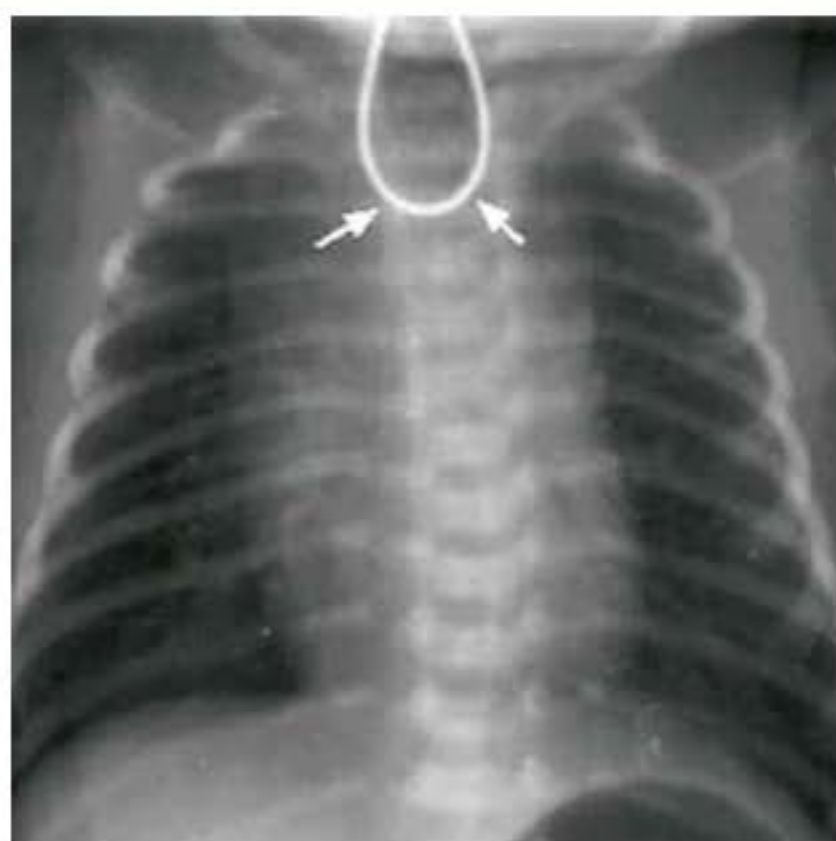
الحدث →



1An... esophageal atresia with distal fistula

CA... with distal fistula

منشور →



1An... esophageal atresia with distal fistula

2An... tt انا عملتها

closure of fistula and 1ry anastmosis

في ناس بتقول هتعمل

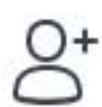esophagostomy and gastristomy and closure
of fistula

عشان المسافه بعيدة



كن أول من يتفاعل

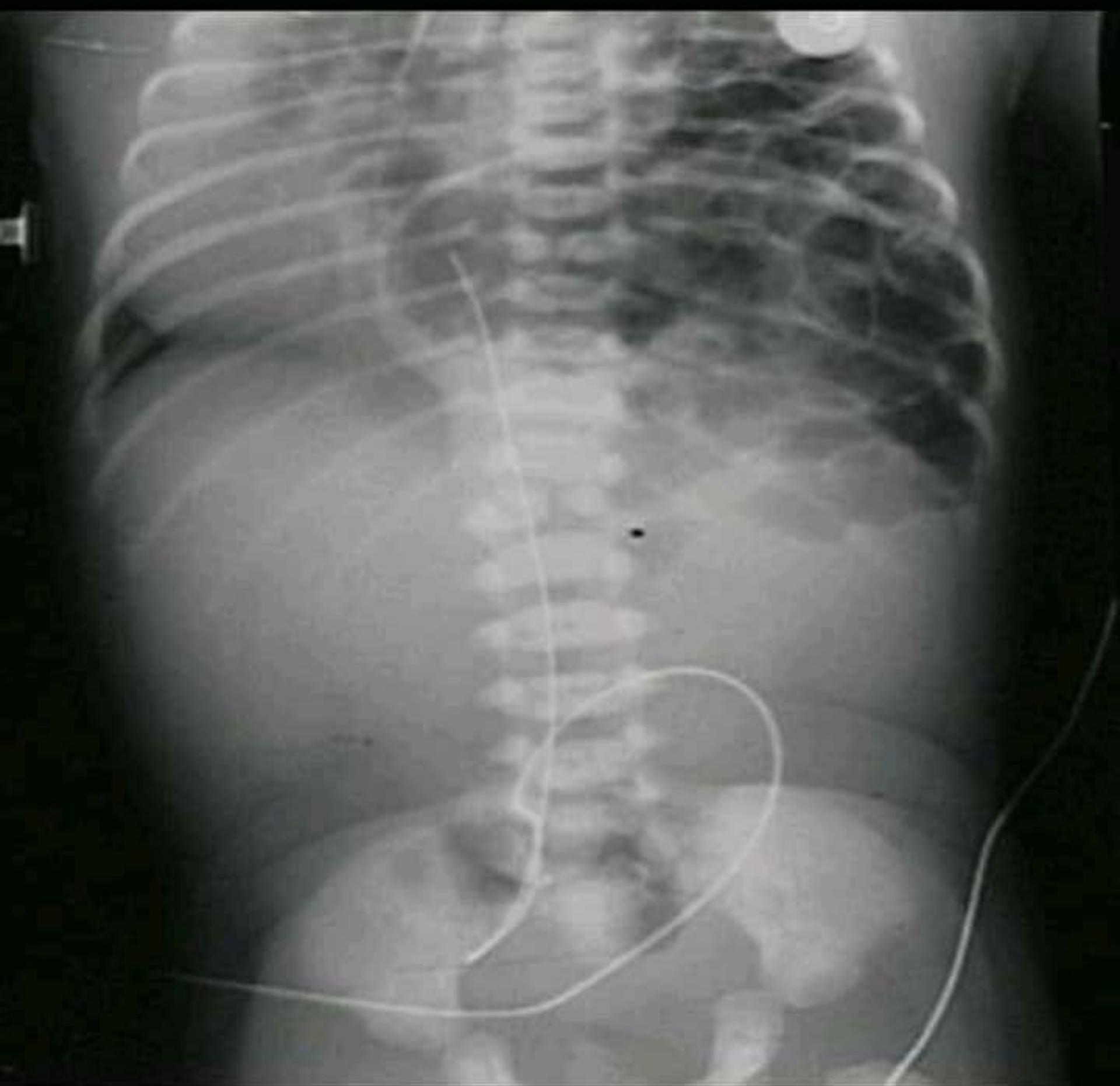إضافة علامات



اكتب تعليقاً...



الحدث →



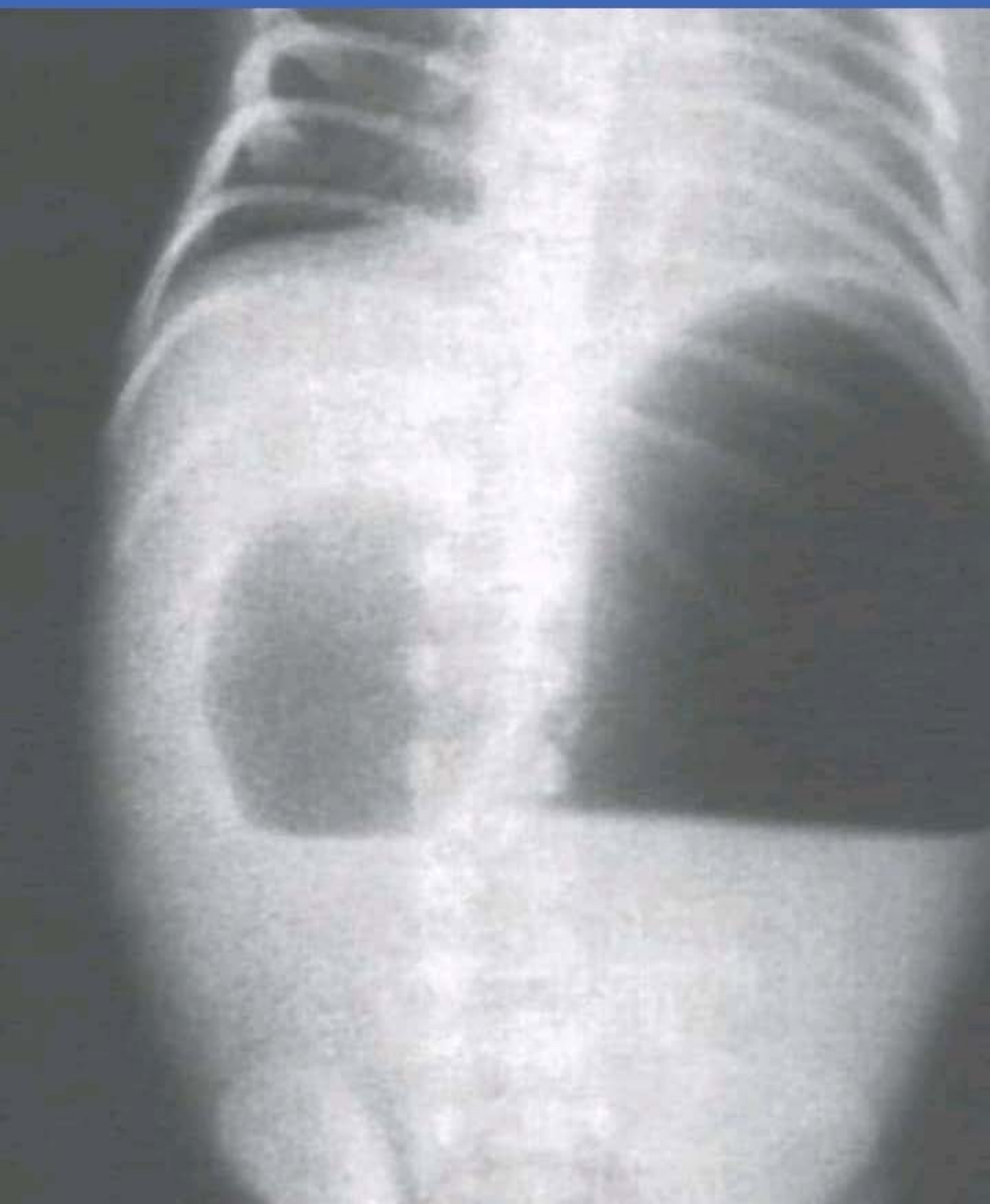
1An... بعالجها امته

stable اما الطفل يبقا

2An... nasogastric tube عشان افضي الهوا



→ الحدث

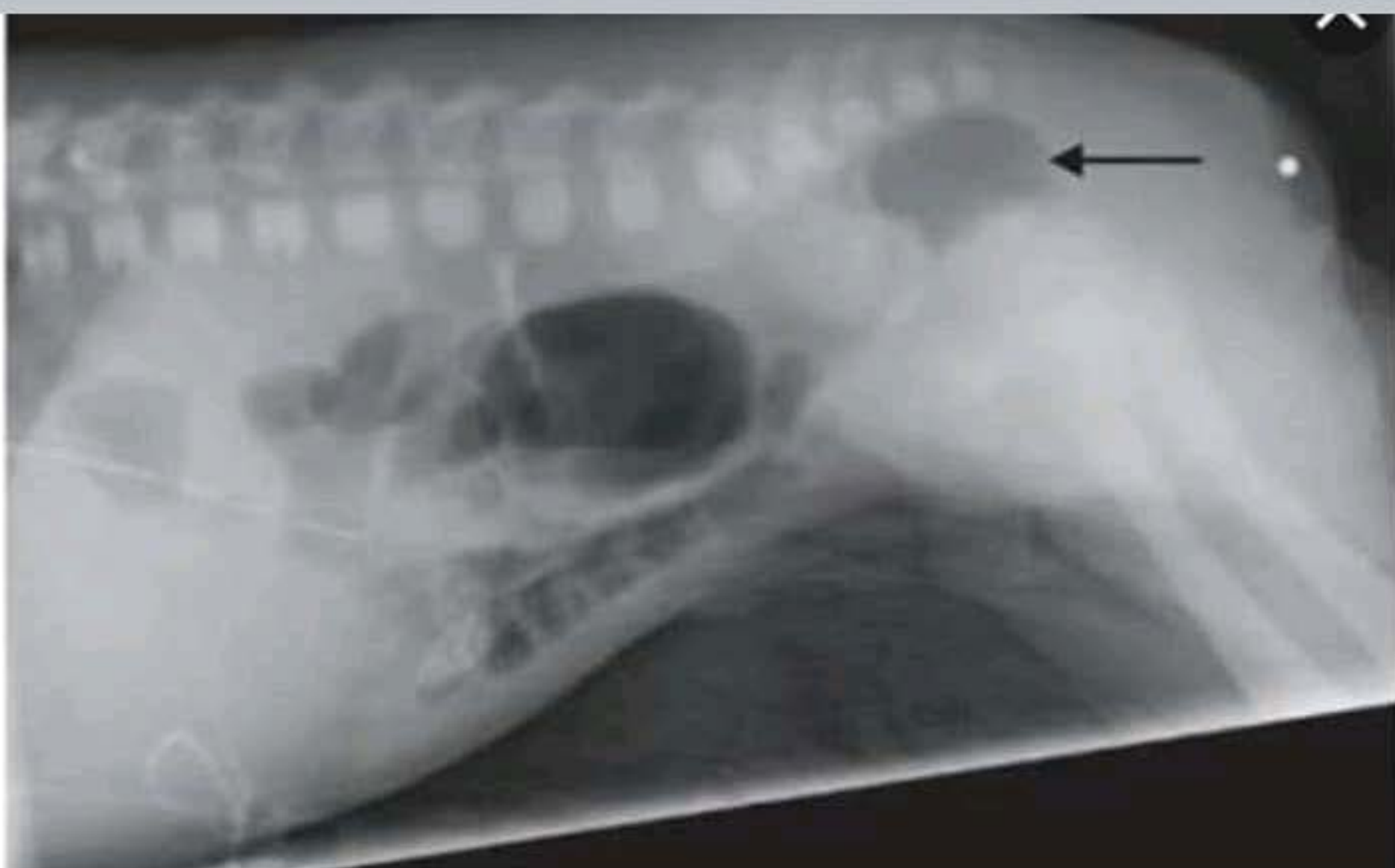


الي فافكره ان السؤال كان
most common associated anomaly
و كانت chromosomal
و كان عليها سؤال كمان

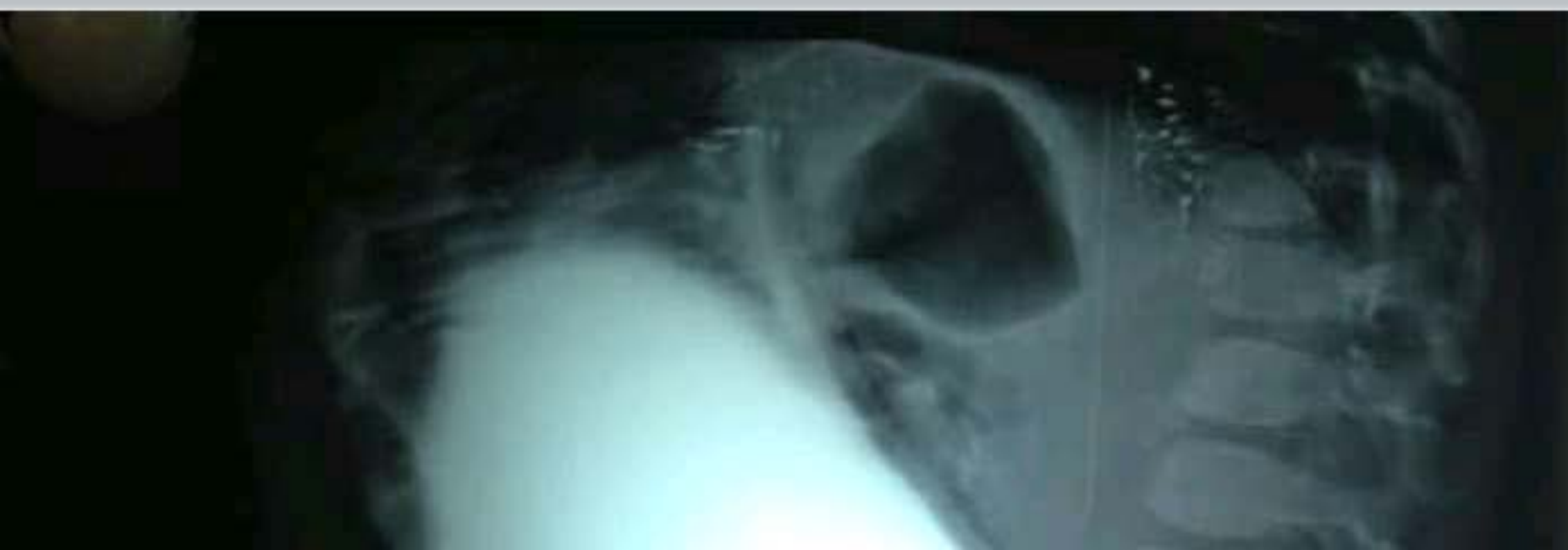

→ الحدث

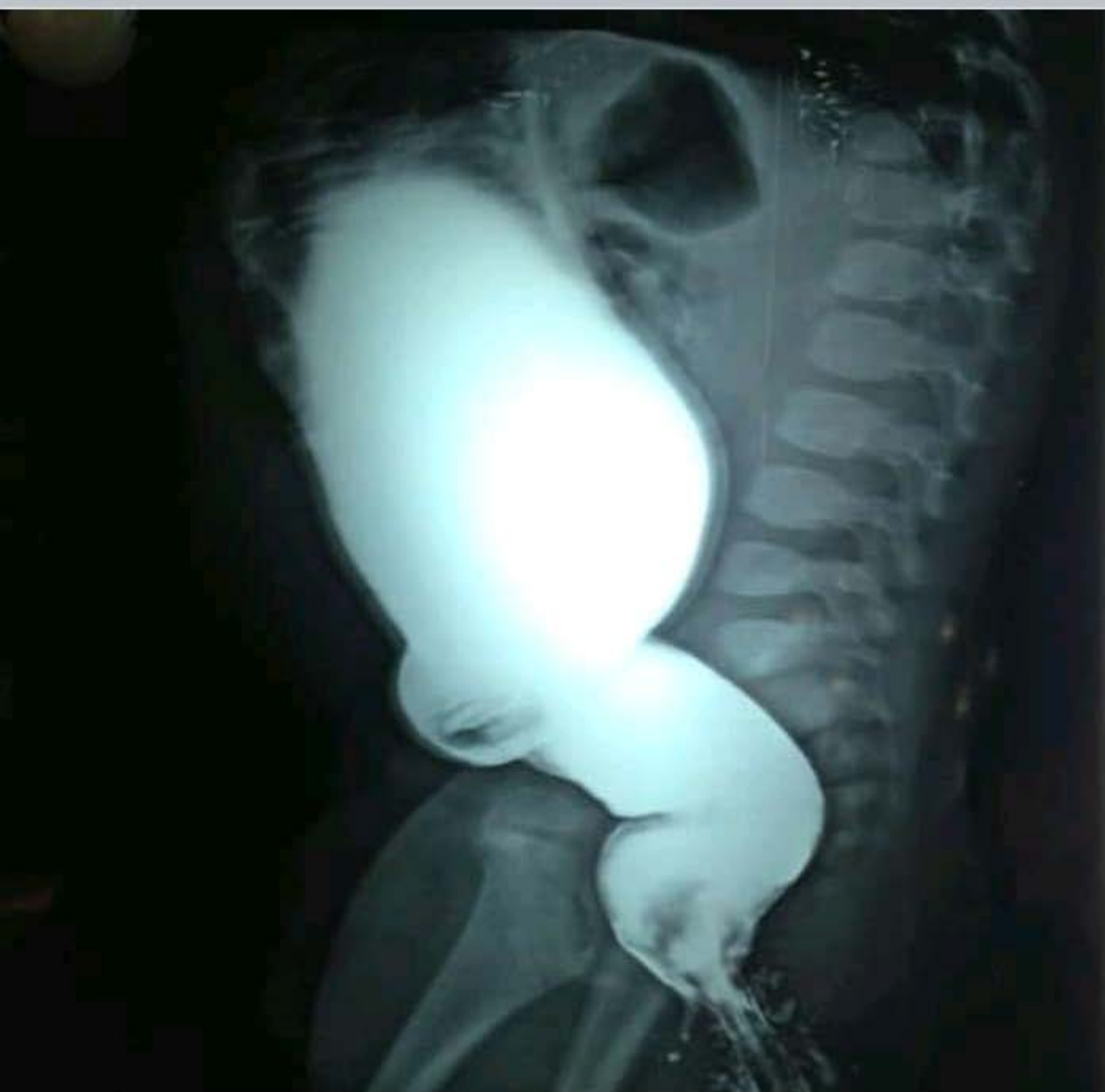المشكلة الأكثر شيوعاً
most common associated anomaly
و كانت chromosomal
و كان عليها سؤال كمان



1An... high anomaly
2An... colostomy



الحدث →



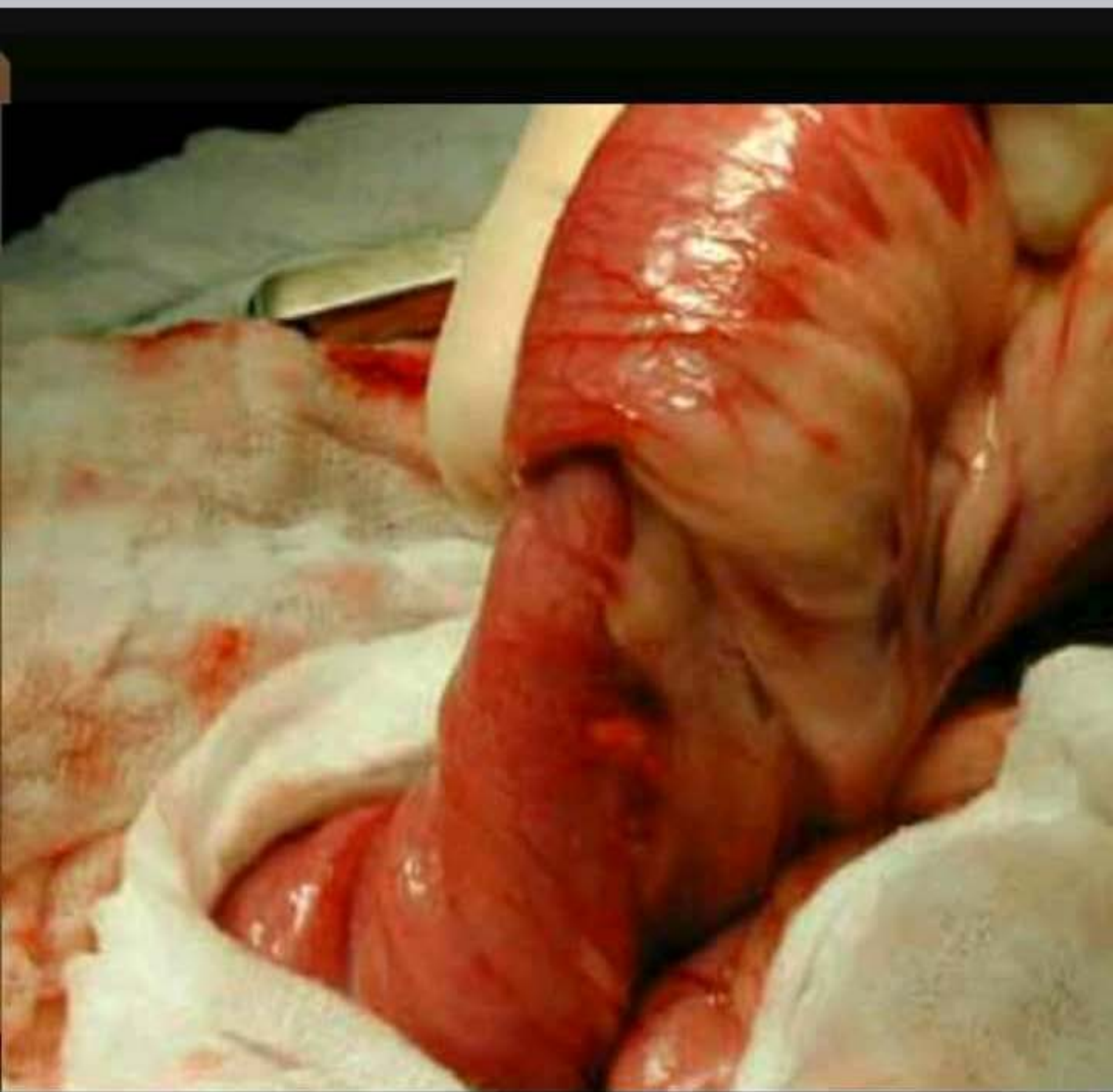
1An... hps

2An...

distended کان عايز الاجابه الغلط و تقريبا كانت ان ال
ganglion cells مافيهاش end



الحدث →



1An... M.C iliocecal

2An.. symptom و كان عايز ايه ال

الي ماشي معاها

most common red jelly stools انا عملتها

